Intraoperative Nerve Monitoring During Peripheral Nerve Release

Introduction and Background

Electrodiagnostic studies continue to play a role in the diagnosis of Tarsal Tunnel Syndrome and other entrapments of peripheral nerves of the lower extremity, with an overall reported accuracy of up to 90%.[1] However, even if a successful diagnosis and location of entrapment is made, it can be difficult to assess that all levels of entrapments have been released during surgery.

Intraoperative neurophysiology monitoring is the use of electrophysiological methods to monitor neural structures during surgery. Although intraoperative electrophysiological recording began in the 1930's its development greatly increased in the 1970's in response to new aggressive surgical treatments for severe spinal deformities.[2] It has since become incorporated into several surgical situations in which there may be a risk for nerve injury.[3]

Although release of peripheral nerves consistently provides a high percentage of relief to patients diagnosed with nerve entrapments, there is still a significant portion of the population that either initially does not get relief or has a return of symptomology related to an incomplete release.[4,5,6,7,8]

The purpose of the study is to illustrate the advantages of using intra-operative nerve testing during tibial nerve release to insure complete alleviation of nerve compression.

Patients and Methods

Seven patients with established peripheral nerve entrapments underwent surgical release with the use of an intraoperative nerve-recording device (NIM, Medtronic). Five patients were revisions and two were primary releases. Preoperative amplitudes were compared to those following the release (**Figures 1 and 2**). Clinical nerve entrapments of ficial peroneal, or common peroneal nerve were determined from clinical presentations and electrodiagnostic studies. An intraoperative nerve recording device was used to acquire pre-operative amplitudes from affected nerves and surgical release was performed (**Figure 3**). Electrodes were placed in the muscle belly of the gastrocnemius, abductor hallucis muscle, and abductor digiti quinti muscle (**Figure 4**). Following the initial decompression of the tibial nerve, intra-operative testing was once again performed. If an increase in tibial amplitude was not seen after traditional release, further nerve decompression is indicated with possible ligation of multiple varicosities.

Results

During the review of this case series, intraoperative increase in the amplitude of nerve recordings was demonstrated in all patients. No complications were noted.

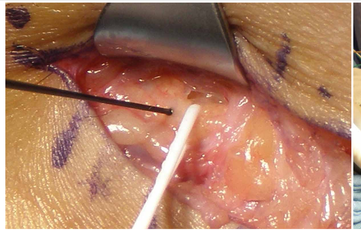

Figure 3

Figure 4

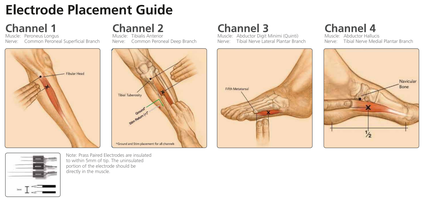

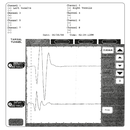

Figure 1:



Figure 2:

Primary Release

Revisions

Established Nerve Entrapments (7 total)

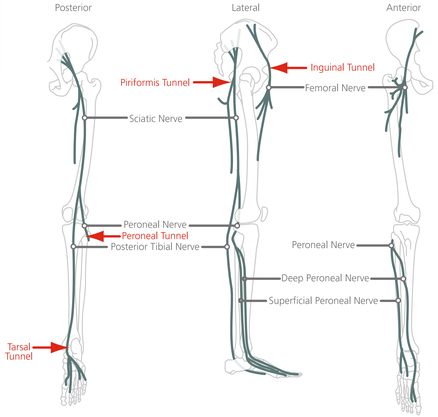

Discussion

The diagnosis of nerve entrapments utilizing electrodiagnostic studies (nerve conduction velocity, electromyography) can help identify the level of entrapment, but do not ensure successful release of the nerve. Introperative nerve recording application to the release of peripheral nerves is a novel technique to improve outcomes. When using intraoperative nerve recording it is recommended to avoid the use of a tourniquet which has been found to alter responses. Also, probes should be applied in the same site and if removal is required it is recommended to mark sites. The intraoperative objective measure described in this report will assist surgeons to perform efficient nerve releases, preventing the need for further procedures.

References:

1. Galardi G, Amadio S, Maderna L, et al. *Electrophysiologic studies in tarsal tunnel syndrome: diagnostic reliability of motor distal latency, mixed nerve and sensory nerve conduction studies.* Am J Phys Med Rehabil 1994; 73: 193-198
2. Tetsuya T, Seiji, K. *History of the development of intraoperative spinal cord monitoring.* Eur Spine Journ; 2007: 16: 140-146
3. Weinzierl MR, Reinacher P, Gilsbach JM. *Combined motor and somatosensory evoked potentials for intraoperative monitoring: intra- and postoperative data in a series of 69 operations.* Neurosurg Rev; 2007:30(2):109-116
4. Cimino WR. *Tarsal tunnel syndrome: review of the literature.* Foot Ankle 1990; 11: 47-52
5. Pfeiffer WH, Cracchiolo A. Clinical results after tarsal tunnel decompression. J Bone Joint Surg Am; 1994: 76: 1222-1230
6. Gondring WH, Shields B, Wenger S. An outcome analysis of surgical treatment of tarsal tunnel syndrome. Foot and Ankle Int; 2003: 24: 545-550
7. Skalley TC, Schon LC, Hinton RY, Myerson NS. Clinical results following revision tibial nerve release. Foot and Ankle Int; 1994: 15: 360-367
8. Vora AM, Schon LC. Revision of peripheral nerve surgery. Foot Ankle Clin; 2004: 9(2): 305-318

Key Contributors:
Edgardo R. Rodriguez, DPM Clinical Instructor
Director: Chicago Foot & Ankle Deformity Correction Center

Shawn Hatfield DPM PGY-3

Matthew Polk DPM PGY-2

Affiliation(s): St. Joseph Hospital/North Chicago DVAMC PM&S-36 Residency Program

Category: Peripheral Nerve Disorders
Type of Submission: Institution
Format: Scientific

Presented: American College of Foot & Ankle Surgeons Scientific National Meeting 2009

Resurrection Health Care

Podiatric Surgical Residency Program
St. Joseph Hospital/North Chicago DVAMC PM&S-36
Program Director
Frank W. Zappa, DPM

©2009 Resurrection Health Care. All Rights Reserved.