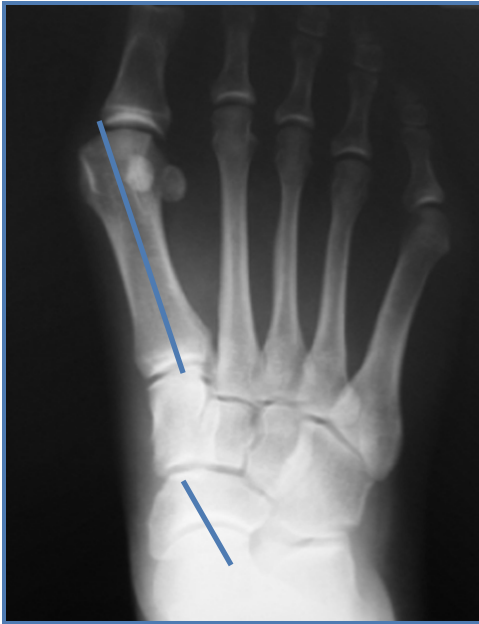

Use of Innovative Locking Plates for Treatment of Flexible Flatfoot Deformity

SURGEON AUTHOR: **Edgardo R. Rodriguez, DPM**, Director, Chicago Foot & Ankle Deformity Correction Center
Attending Staff: Neurologic & Orthopedic Hospital of Chicago

CONTRIBUTING AUTHOR: **Shawn Hatfield, DPM**, PGY-3 Saint Joseph Hospital, Chicago, IL



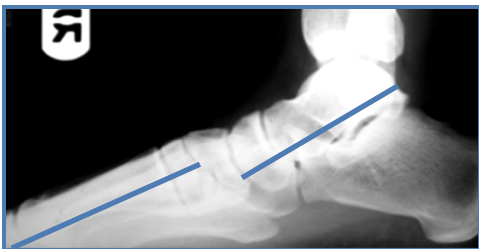A 30-year-old female patient presented with severe flexible flatfoot and subtalar joint pain. She denied any previous trauma or surgical treatment for flatfoot correction. Past medical history and review of symptoms were unremarkable other than the area of chief complaint. Gait evaluation illustrated significant rearfoot valgus and lateral deviation of the forefoot in the transverse plane. Evaluation of pre-operative radiographic views showed deviation of the talar and first metatarsal alignment **FIGURES 1 & 2**.

Introduction

Flexible flatfoot deformity is a decrease in the medial arch that is passively corrected through manipulation by the examiner. Frequently an equinus contracture is seen in conjunction with a rearfoot valgus deformity. This may also be accompanied by a concomitant forefoot varus deformity. At late stages of the pathologic process, the tibialis posterior tendon becomes insufficient and allows its antagonist, the peroneus brevis tendon, to become contracted and contribute as a deforming force.

Diagnosis of flexible flatfoot deformity is often made clinically by evaluating the patient sitting, standing, and during the gait cycle. Radiographic changes often include an abnormal Meary's line, increased talar declination, talar head uncovering, and a decreased calcaneal inclination angle.

Treatment options should begin with conservative measures. Many patients benefit from a custom arch support and physical therapy to alleviate soft tissue contractures. However, if pain and deformity persist, the treating physician should consider surgical correction of the deformity. Upon surgical evaluation, the surgeon must consider the differing planes of deformity and address both soft tissue and osseous structures.¹



FIGURES 1 & 2: Pre-Op X-rays, AP & Lateral

Surgical Technique

First Procedure:

The first procedure performed is the release or lengthening of the posterior compartment contracture. A gastroc recession or achilles tendon lengthening is accomplished in the posterior aspect of the lower leg to eliminate the equinus of the ankle and allow realignment of the hindfoot.

Second Procedure:

The correction of the hindfoot valgus is accomplished by a medializing calcaneal slide osteotomy in which the direction of the pull of the achilles tendon is medialized. This type of osteotomy enhances the supination of the hindfoot. The incision is placed inferior to peroneal tendons at the level of the lateral aspect of the calcaneus and inferior to the sural nerve. The incision is made perpendicular to the long axis of the calcaneus in the sagittal plane. The dissection is carried down bluntly to the level of the calcaneus. The osteotomy is performed by osteotomes or power instrumentation and is made parallel to the skin incision. The orientation of the osteotomy is from lateral to medial. Care should be taken to stay posterior to the facet of the subtalar joint. The osteotomy should be greensticked at the medial cortex to avoid damage to the neurovascular bundle.

The plate is positioned on the lateral aspect of the calcaneus and a non-locking screw is placed at the calcaneal tuberosity. A second non-locking screw is placed just inferior to the subtalar joint at the distal aspect of the plate construct. The non-locking screws are going to push the plate flush with the calcaneal wall prior to insertion of the locking screws. Locking screws are inserted into the remaining screw holes **FIGURE 3**. When placing locking screws, it is important to thread on the locking drill guide into the screw hole prior to drilling to insure flush screw placement and reduce the risk of cross threading the screw heads with the plate holes.

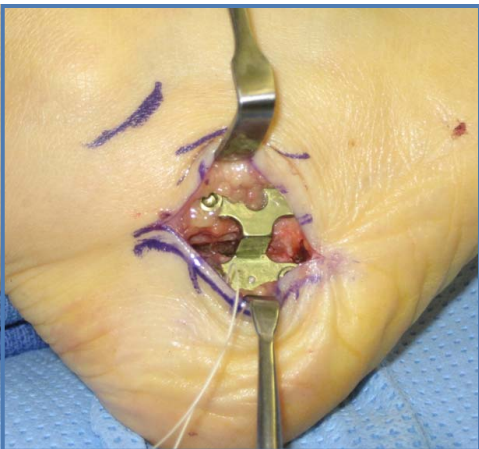


FIGURE 3: Medial Calcaneal Slide Osteotomy

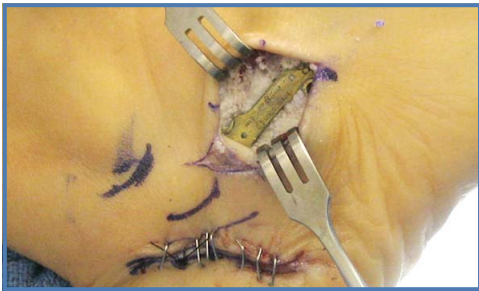


FIGURE 4: Evans Calcaneal Lengthening

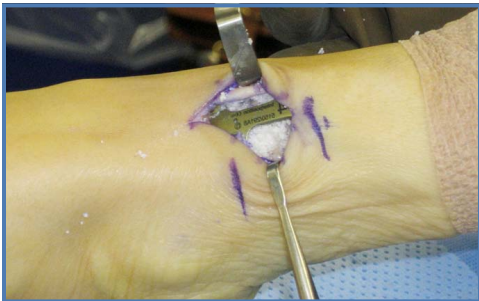
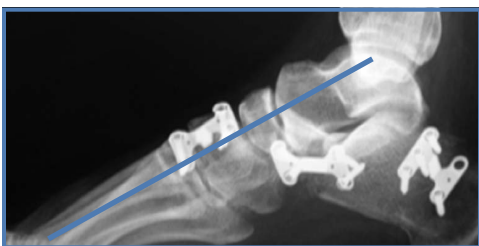
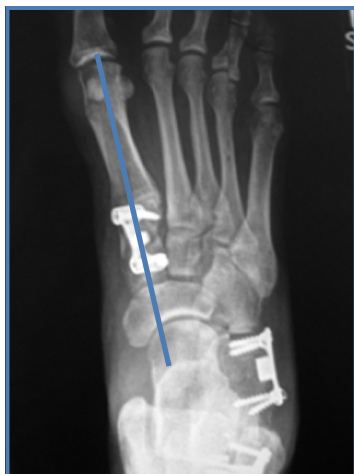FIGURE 5: Cotton Osteotomy



FIGURES 6 & 7: Post-Op X-rays, AP & Lateral

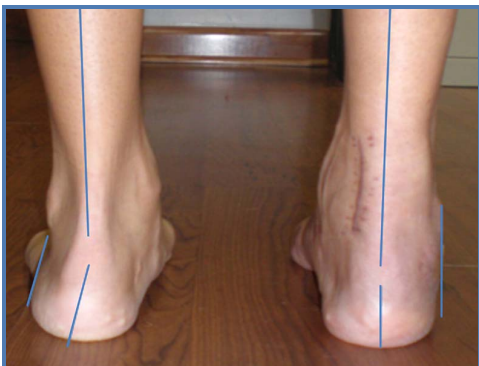

FIGURE 8: Frontal Hindfoot Correction

Third Procedure:

When midtarsal joint instability is noted after the medial calcaneal slide osteotomy, an Evans calcaneal lengthening may be required to correct the transverse plane and provide midtarsal joint stability. The lateral column lengthening is performed by placing a 2-3 cm longitudinal incision lateral to the anterior process of the calcaneus. It is important not to make this incision vertically as lengthening the lateral column can create wound closure problems. Blunt dissection is carried down to the level of the peroneal tendons, which should be retracted plantarly. The sural nerve may also be encountered and retracted plantarly. Once the incision is carried to the periosteum of the anterior calcaneal process, the calcaneal cuboid joint is then identified. The osteotomy is performed approximately 1-1.5 cm proximal to the joint to avoid articular damage. When creating the osteotomy, the surgeon must remain cognizant of the medial structures. The knot of Henry can be damaged by overzealous use of the cutting instrument. After completion of the osteotomy, the interpositional block plate is then placed within the osteotomy with the use of a laminar spreader or hemostat. The forefoot should then be loaded to insure adequate lengthening of the lateral column has been achieved. When placing the plate at this level, the surgeon will likely encounter the peroneal tubercle. Slight manipulation of the plate placement can insure proper and flush placement. Either locking or non-locking screws can be placed for stability according to surgeon preference **FIGURE 4**. Orthobiologics can be used at the surgeon's discretion.

Fourth Procedure:

If forefoot varus is a factor, then a Cotton osteotomy or plantarflexory osteotomy at the level of the medial cuneiform may be required. A forefoot varus is often encountered following a lateral column lengthening procedure. A 2-3 cm longitudinal incision is placed dorsally over the body of the medial cuneiform. Blunt dissection is carried to the level of the tibialis anterior tendon, which should be retracted medially. The first metatarsal cuneiform and the navicular medial cuneiform joints should be identified. The osteotomy is performed in the coronal plane in the middle of the medial cuneiform to avoid articular injury. The plantar cortex should be left intact to add stability to the osteotomy and aid in planar deformity correction. A bi-planar correction can be achieved by placing the interpositional block plate at the dorsomedial aspect of the osteotomy. This will allow plantarflexion and adduction of the first ray. If only the sagittal plane requires correction, the plate should be placed dorsally. After placement of the plate, the locking or non-locking screws are placed in an effort to avoid the articulation at either side of the osteotomy **FIGURE 5**.

Post-Operative Results

X-Ray imaging shows the reduction of the talar and first metatarsal angles **FIGURE 6 & 7**. A Cotton procedure was performed to correct the first metatarsal alignment with a dorsal medial block plate at the level of the medial cuneiform. Plantarflexion of the first metatarsal corrected the sagittal plane deformity by eliminating the first ray dorsiflexion, or forefoot supinatus. The anterior lateral calcaneal plate corrected the transverse plane deformity by lengthening the lateral column. This interpositional block plate equates to the classical Evans osteotomy with an interpositional tricortical bone graft by lengthening the lateral column and realigning the midtarsal joint. The step plate corrected the hindfoot in the frontal plane by medializing the calcaneal tuberosity and assisting in supination of the subtalar joint **FIGURE 8**.

The post-operative course generally consists of non-weight-bearing status to the lower extremity of four to six weeks. Once trabeculation is noted at the osteotomy sites, the patient may begin partial weight bearing with the use of crutches or other assistive gait devices. Physical therapy should also be administered at this time to shorten the overall recovery time by decreasing swelling and improving strength and range of motion.

Discussion

Locking displacement and block plates are viable options for the treatment of flexible flat-foot deformity. This innovative fixation system allows the surgeon to provide an exact predetermined amount of translation or lengthening to any osteotomy. The locking plate construct allows its use in patients with osteopenic bone and is very amenable to autograft or allograft use. The low-profile nature of this plating system also allows for easy wound closure following the procedure and prevents common problems associated with painful hardware placed through the plantar aspect of the foot.

For additional information or to order reprints, please contact Ascension Orthopedics at 512-836-5001, 877-370-5001 (U.S. toll-free), or visit www.ascensionortho.com.